

CASE REPORT

Evaluating Ductus Venosus absence by three-dimensional ultrasonography

Aikaterini Karavida¹, Apostolos Zavlanos², Ioannis Dimitrakopoulos³, Vera Kelesidou⁴,
Apostolos Athanasiadis⁴

¹Prenatal Diagnostic Center, Thessaloniki, Greece

²Prenatal Diagnostic Center, Thessaloniki, Greece

³GE Healthcare, Thessaloniki, Greece

⁴3rd Department of Obstetrics & Gynecology, Aristotle University of Thessaloniki, Thessaloniki, Greece

ABSTRACT

Absence of ductus venosus in the fetus is a rare finding. Prognosis in these cases is determined by the extent of portal system development. Three dimensional ultrasound images visually reconstruct the complex

course of fetal vessels, which with two dimensional ultrasound in most cases is unattainable, establishing proper diagnosis and enabling appropriate counseling.

KEY WORDS

ductus venosus absence, 3D ultrasonography, Abernethy malformation, portosystemic shunt

The absence of ductus venosus (DV) in the fetus is a rare finding (0,04%), that is increasingly being recognized in the detailed first trimester ultrasound examination [1]. In these cases, there is an increased risk for portal system malformations and abnormal portosystemic shunts, diverting portal blood to the inferior vena cava (IVC). An extrahepatic shunt that may connect to variable sites of the systemic circulation is named Abernethy malformation, and can be readily visible in fetal ultrasound examination [2]. Prognosis is mainly determined by the extent of portal system development.

This is the three-dimensional (3D) Doppler ultrasound image (GE Voluson E10) at gestational age 24+6 weeks, showing the normally developed portal system and the discontinuation of the normal sequence of the umbilical vein (UV) due to absence of DV (Figure 1). An aberrant

vessel (AV) emerges from the UV just below the umbilicus, and coursing above the bladder and between the umbilical arteries (UAs), anastomoses with the IVC. Color depicts opposite direction of blood flow in the AV than in the UAs. Thus, this case was diagnosed as an Abernethy malformation Type 2, since there is a normal portal system and the AV functions as a shunt, diverting umbilical blood directly to the IVC. Fetal karyotype was normal. The fetus was delivered vaginally at term, weighing 2.800 g. Transient hyperbilirubinemia was observed during the neonatal period, and the infant is reported as asymptomatic at four months of age.

The pathophysiological significance of DV absence in the fetal state of circulation is not yet fully understood. Establishment of connection between umbilical and systemic circulation is critical for the viability of the early embryo. This

Corresponding author

Aikaterini Karavida

Obstetrician, Gynecologist, Prenatal Diagnostic Center, Ag. Sofias 15, 54623, Thessaloniki, Mob: +30 6974426318, Email: aa.karavida@gmail.com

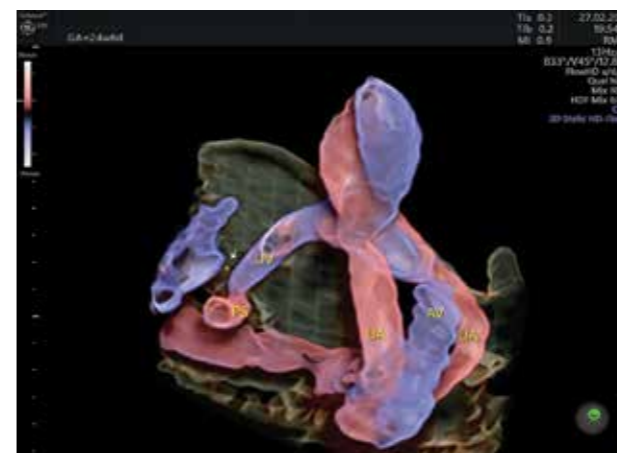


Figure 1: Three-dimensional (3D) Doppler ultrasound image of ductus venosus (DV) absence at 24+6 weeks. The DV is absent (arrow *) and umbilical blood flow is diverted to the inferior vena cava by an aberrant vessel (AV). UV: umbilical vein, UA: umbilical artery, PS: portal system.

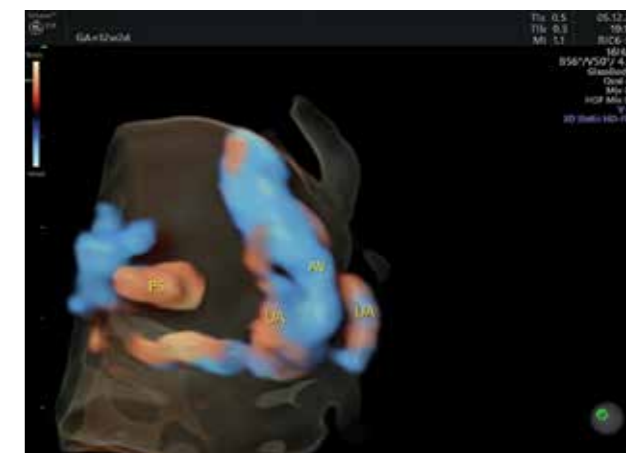


Figure 2: Three-dimensional (3D) Doppler ultrasound image of ductus venosus (DV) absence at 12+2 weeks. Umbilical blood flow is diverted to the inferior vena cava by an aberrant vessel (AV). UA: umbilical artery, PS: portal system.

connection is formed in the fetal liver through the portal circulation and the hepatic veins, and through the DV which physiologically bypasses the liver. The liver then becomes the 'metabolic brain' of the fetus by regulating the amount of umbilical blood that passes through the liver parenchyma or bypasses it via the DV directly to the infracardiac portion of the IVC. The effect on fetal wellbeing due to replacement of the DV by an abnormal extrahepatic shunt is not clear. The prognosis for postnatal life though, is primarily determined by the possibly coexisting portal system abnormalities and not by the size or type of fetal shunt. If the portal vein is absent, as in Abernethy malformation type 1, there is an increased risk for hepatic failure requiring transplantation as well as hepatic malignancies later in life [3].

Consequently, visualizing the integrity of the fetal portal system is very important for prenatal counseling, and it is ultrasonographically more challenging than identifying the usually large bore aberrant vessel. It is of note that most of the above described vascular configurations were identifiable at gestational age 12+2, but they were not considered adequate for definite diagnosis (Figure 2). Optimization of volume acquisition and rendering settings could possibly have resulted in even more informative 3D images in the first trimester.

Three-dimensional ultrasound images visually reconstruct the complex course of fetal vessels, which with 2D in most cases is unattainable, establishing proper diagnosis and enabling appropriate counseling. ■

REFERENCES

1. Pacheco D, Brandao O, Montenegro N, Matias A. Ductus venosus agenesis and fetal malformations: what can we expect? – a systematic review of the literature. *J Perinat Med* 2019; 47(1): 1-11
2. Athanasiadis A, Karavida A, Chondromatidou S, Tsiouridis J, Tarlatzis B. Prenatal diagnosis of Abernethy malformation by three-dimensional ultrasonography. *Ultrasound Obstet Gynecol* 2015; 46: 638–639
3. Morgan G, Superina R. Congenital absence of the portal vein: two cases and a proposed classification system for portosystemic vascular anomalies. *J Pediatr Surg* 1994; 29: 1239–1241.

CITATION

Karavida A, Zavlanos A, Dimitrakopoulos I, Kelesidou V, Athanasiadis A. Evaluating Ductus Venosus absence by three-dimensional ultrasonography. *OGI* 2021; 1(1): 58-59.